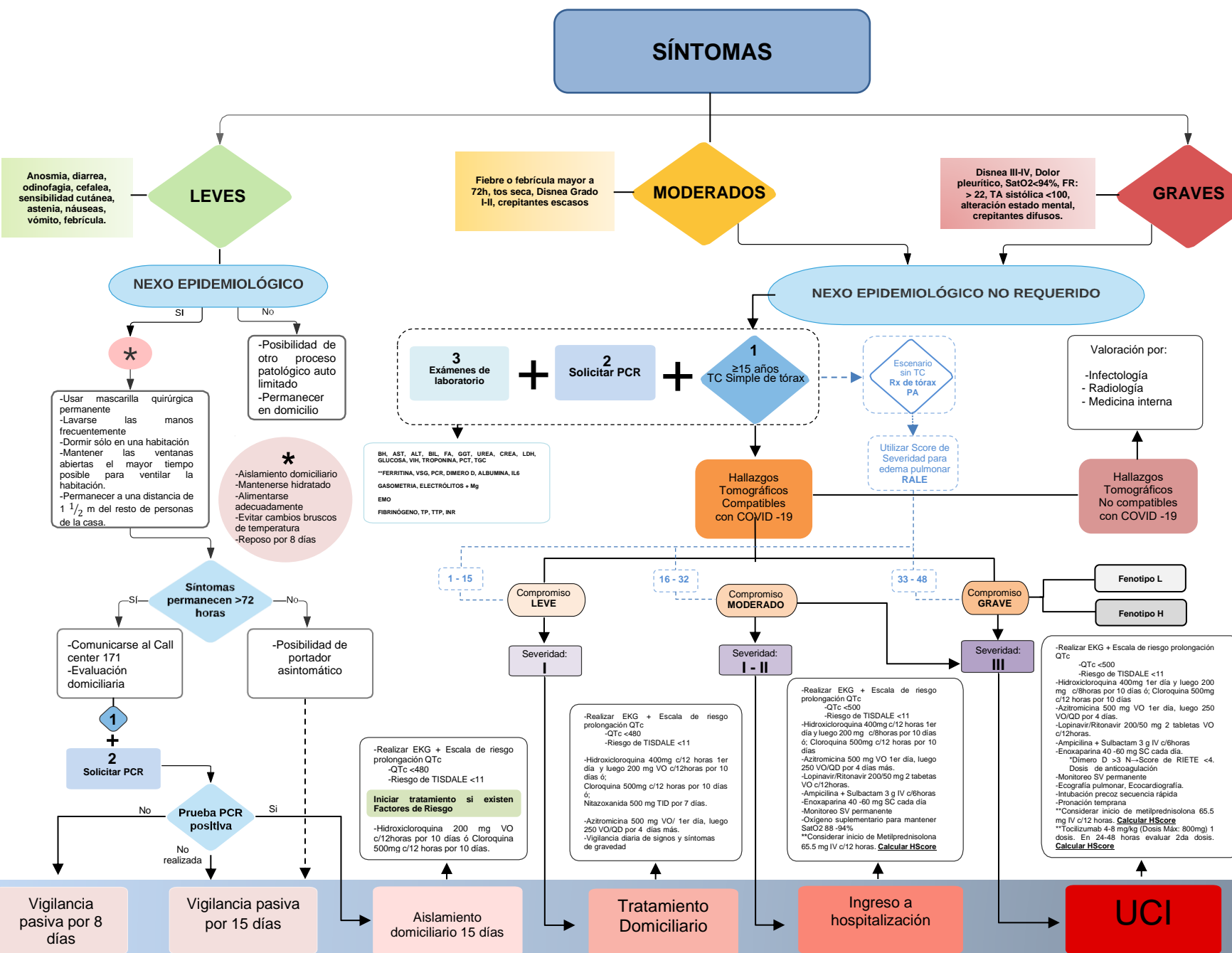


# ALGORITMO PARA EL ABORDAJE INICIAL DE ADULTOS CON SOSPECHA DE COVID 19



FACTORES DE RIESGO	
Edad ≥60 años, ó	Enfermedad cardíaca crónica ó HTA, ó
IMC ≥30, ó	Enfermedad pulmonar crónica, ó
Diabetes (HbA1c), ó	Inmunodeprimidos

HALLAZGOS TOMOGRÁFICOS COMPATIBLES CON COVID-19
*Opacidades en vidrio deslustrado (bilateral, subpleural, periféricas)
*Patrón en empedrado
*Consolidación del espacio aéreo
*Engrosamiento del intersticio peribroncovascular

HALLAZGOS TOMOGRÁFICOS NO COMPATIBLES CON COVID-19
-Adenopatías
-Derrame pleural
-Árbol en gemación
-Cavitaciones
-Neumotórax

PORCENTAJE DE COMPROMISO POR LÓBULO X TIPO DE PATRÓN			
TIPO DE PATRÓN	#	DENSIDAD	#
0 - 29	1	Vidrio deslustrado	1
30 - 70	2		2
>70	3	Consolidación	3
TOTAL (LSD = LM + LID + LIS + LIL (MÁX 30 puntos))			
LEVE	0-9 PUNTOS	MODERADO	10-20 PUNTOS
		GRAVE	20 PUNTOS

RALE			
Dividir en 4 cuadrantes Rx de tórax			
EXTENSION	PUNTOS	DENSIDAD	PUNTOS
Nada	0	Nada	0
<25%	1	Levemente	1
25 - 50%	2	denso	2
50 - 75%	3	Moderado	2
>75%	4	Denso	3
TOTAL: Q1 + Q2 + Q3 + Q4 (Máximo 48 Puntos)			

FENOTIPOS	
L	Patrón dominante de vidrio deslustrado
H	Patrón dominante de ocupación del espacio aéreo

ESCALA RIESGO DE TISDALE	PUNTAJE
Bajo	≤ 6
Moderado	7-10
Alto	≥ 11

ESCALAS	Severidad
CURB 65: 0-1; ó qSOF: 0; ó PAFI: >300	I
CURB 65: 2; ó qSOF: 1; ó PAFI: 200 a 300	II
CURB 65: 3 ó < 0; ó qSOF: A-2; ó PAFI: <200	III

## BIBLIOGRAFÍA

1. Enfermedad por coronavirus, COVID-19 Actualización: 17 de marzo 2020 documento técnico gobierno de España.
2. Philippe Galet Jean-Christophe Lagier, Hydroxychloroquine and azithromycin as a treatment of COVID-19: results of an open-label non-randomized clinical trial. International Journal of Antimicrobial Agents. 2020. doi:https://doi.org/10.1016/j.ijant.2020.105940.
3. Sun Zhen, Zhang Ming, Dai Jie, et al. COVID-19: a recommendation to examine the effect of hydroxychloroquine in preventing infection and progression. Journal of Antimicrobial Chemotherapy. 2020; doi:10.1093/acq/ciaa114. Published: 20 March 2020
4. Tang YN, Bai H, Chang XJ, Gong J, Li Z, Sun Z, et al. Anticoagulant treatment associated with decreased mortality in severe coronavirus disease 2019 patients with coagulopathy. J Thromb Haemostasis. 2020 Mar 27. doi:10.1111/jth.14817.
5. Chinese Guidelines for Invasive Diagnosis of COVID-19. 2020; Available at: <http://www.chinacdc.cn/>
6. Tsao AC, Yang D, Fauci AS, et al. Clinical course and risk factors for early mortality and ICU admission in COVID-19. medRxiv. 2020. doi:10.1101/2020.03.09.20056670.
7. Tsao AC, Yang D, Fauci AS, et al. Clinical course and risk factors for early mortality and ICU admission in COVID-19. medRxiv. 2020. doi:10.1101/2020.03.09.20056670.
8. NGS 2 Ming Yen, LEI E, Blana PP, YANG J, et al. Imaging Profile of the COVID-19 Infection: Radiologic Findings and Literature Review. Radiology. 2020; Available at: <https://pubs.rsna.org/>
9. Meta-analysis COVID-19 CLIA: TENDENCIAS PARA COVID-19. MSF. 2020.
10. Coronavirus Disease 2019 (COVID-19) [Internet]. Centers for Disease Control and Prevention. 2020 [cited 1 April 2020]. Available from: <https://www.cdc.gov/coronavirus/2019-nCoV/hq-therapeutic-update.html>
11. American College of Cardiology. 2020. Ventricular Arrhythmia Risk Due To Hydroxychloroquine/Azithromycin Treatment For COVID-19. American College of Cardiology. [online]. Available at: <https://www.acc.org/press-releases/2020/03/27/14000/ventricular-arrhythmia-risk-due-to-hydroxychloroquine-azithromycin-treatment-for-covid-19> [Accessed 2 April 2020].
12. The Lancet Journals. 2020. COVID-19: Consider Cerebral Swelling Syndrome And Hemorrhagic Disposition. [online]. Available at: <https://www.thelancet.com/journal/2020/03/28/01473-20200328-01473e> [Accessed 2 April 2020].
13. Lung, C. 2020. Coronavirus Pleumia As A Potential Therapy For COVID-19. [online]. The Lancet Journals. Available at: <https://www.thelancet.com/journal/2020/03/28/01473-20200328-01473e> [Accessed 2 April 2020].
14. Ruff, C. 2020. Coronavirus Pleumia As A Potential Therapy For COVID-19. [online]. The Lancet Journals. Available at: <https://www.thelancet.com/journal/2020/03/28/01473-20200328-01473e> [Accessed 2 April 2020].
15. Gattinoni L, et al. COVID-19 pneumonia: different respiratory treatment for different phenotypes? [online]. Intensive Care Medicine. DOI: 10.1007/s00134-020-09033-2
16. Radiology. 2020. Chest Imaging And COVID-19. RSNA Publishes Pulmonary Society Consensus Statement. [online]. Available at: <https://pubs.rsna.org/>
17. Warren M, Zhao Z, Royappa T, Banerjee J, Shaver C, Smiter M, Rice T, Mathay M, Calfee C, and Witek L. 2019. Severity Scoring Of Lung Oedema On The Chest Radiograph Is Associated With Clinical Outcomes In ARDS. [online]. Available at: <http://dx.doi.org/10.1139/Thor-2017-211280> [Accessed 11 April 2020].
- 18.
- 19.

## AUTORES

Dr. Fabián Lozano Samaniego\*  
 Dr. Alexander Lozano Samaniego\*  
 Dr. Nelson Delgado Torres\*\*  
 Dr. Daniel Pacheco Montoya\*  
 Dr. Carlos Jaramillo Cueva\*  
 Dra. Shyla Cosentino\*  
 Est. Santamía Maldonado Rivera\*

\*Internista-Intensivista, \*\*Radiólogo Cardiorritmólogo,  
 \*\*Infectólogo, Internista, \*Cirujano Vascular, Emergenticólogo,  
 \*Estudiante Medicina UTPL. Hospital General Isidro Ayora